# DETECTION OF VISUAL IMPAIRMENTS USING BACK PROPAGATION NEURAL NETWORKS

Anwar Basha.H[1], S.Udhayakumar[2], E.Sujatha[3]
Assistant Professor[1,2], Associate Professor[3]
Department of Computer Science and Engineering
S.A. Engineering College, Chennai, India.
E-mail: anwar.mtech@gmail.com[1]
udhayakumarsoft@gmail.com2
sanjaymohankumar@gmail.com[3]

**Abstract-Proliferative diabetic retinopathy is the more serious conditions as it involves the proliferative growth of abnormal new vessels on the retina. New vessels characteristic appearance like narrower calibre and more tortuous. This paper presents a method for detecting new vessels on the optic disc based on the SVM classifier. First, vessels like candidate segments are extracted using green component, because in the colour retinal images the blood vessels appear most contrasted in the green channel compared to red and blue channels in RGB image. Second, candidate new vessel segments re detected using a method of morphological watershed transform. Third, fifteen feature parameter are calculated for each segment. Based on these feature, each segment is classified as normal or abnormal vessels using SVM classifier. The system was trained with normal and abnormal retinal images.**

**Index terms-**Proliferative diabetic retinopathy, Retina, SVM classifier, watershed transforms.

## I. INTRODUCTION

Diabetic retinopathy is a complication of diabetes that results from damage to the blood vessels of the light-sensitive tissue at the back of the eye (retina). At first, diabetic retinopathy may cause no symptoms or only mild vision problems. Eventually, however, diabetic retinopathy can result in blindness. Too much sugar in your blood can damage the tiny blood vessels (capillaries) that nourish the retina. This can result in diabetic retinopathy and vision loss. Elevated blood sugar levels can also affect the eyes' lenses. Diabetic retinopathy is usually classified as early or advanced. Early diabetic retinopathy that is, Nonproliferative diabetic retinopathy (NPDR) is the most common type of diabetic retinopathy. It can be described as mild, moderate or severe. When you have NPDR, the walls of the blood vessels in your retina weaken.

Advanced diabetic retinopathy Proliferative diabetic retinopathy (PDR) is the most severe type of diabetic retinopathy. When you have PDR, abnormal blood vessels grow in the retina. Sometimes the new blood vessels grow or leak into the clear, jelly-like substance that fills the center of your eye (vitreous). Eventually, scar tissue stimulated by the growth of new blood vessels may cause the retina to detach from the back of your eye. Proliferative Diabetic Retinopathy can be seen in the eye with an ophthalmoscope as neovascularization, a proliferative growth of abnormal new blood vessels. Neovascularization appears as a twisted collection of blood vessels and is quite dangerous because these vessels grow abnormally out of the retina into the clear vitreous gel.

The rest of the paper deals with the following sections: section II discuss about the related works, section III discuss about the classification method of the proposed work, section IV describe the experimental results and discussion, section V about the conclusion of the paper.

## II.RELATED WORKS

Walter et al deals with the detection of exudates [1].Exudates are found using their high grey level variation, and their contours are determined by means of morphological reconstruction techniques. Robustness and accuracy in comparison to human graders have been evaluated on a small image database.

Niemeijer et al presents the Machine learning– based automated system capable of detecting exudates and cotton-wool spots and differentiating them from drusen in color images obtained [8]. If the machine learning can be improved with additional training data sets, it may be useful for detecting clinically important bright lesions, enhancing early diagnosis, and reducing visual loss in patients with diabetes.

Sopharaka et al deals with an automatic method to detect exudates from low-contrast digital images of retinopathy patients with non-dilated pupils using a fuzzy c-means (FCM) clustering technique [10]. The number of required clusters was optimally selected from a quantitative experiment and cluster optimization was based on sensitivity and specificity.

Osareh et al presents the computational intelligence based approach for the detection of Exudates [11]. Through this system, the abnormal retinal images are automatically discriminated from normal images, this provides a huge amount of savings in terms of the number of retinal images that require to be manually reviewed by the medical professionals.

Larsen et al deals with the detection of red lesions that is micro aneurysms, hemorrhages. The simplest automatable task of practical utility is probably that of distinguishing between subjects without retinopathy and those with any level of retinopathy [2]. This paper addresses a novel red lesion detection method is presented based on a pixel classification and feature selection [4].

Walter et al presents the computer assisted diagnosis of diabetic retinopathy [7]. The easiest ways to diagnose DR is the analysis of color fundus images the most important lesions of DR is visible in this type of images. In this paper [9], they introduce a new template-matching based algorithm to detect MAs. Detecting MAs in the retina, based on template-matching in the wavelet domain. The examination time and effect on the patient could be reduced.

Niemeijer et al deals with the international competition of the detection of micro aneurysms organized by Retinopathy Online challenge [13]. Multiyear online competition for this competition, they compare the results of five different methods, produced by five different teams of researchers on the same set of data.

Staal et al presents a method for automated segmentation of vessels in two-dimensional color images of the retina [3]. In this paper, evaluation has been done using accuracy of hard classifications and values of soft classifications.

Sofka et al presents a method for detection of low contrast and narrow vessel and eliminating false detection at nonvascular structure [5]. A new technique likelihood ratio test is presented for extracting vessels in retinal images which combine matched-filter response, confidence measures and vessel boundary measures.

Harihar et al presents a fully automated approach for monitoring the longitudinal state changes of diabetic retinopathy [6]. Bayesian detection and Classification algorithms are used. The results show that once the changes are detected, the classification is achieved with a very high precision.

Saiprasad et al deals a robust and computationally efficient approach for the localization of the different features and lesions in a fundus retinal image [12]. They also show that many of the features such as the blood vessels, exudates and micro aneurysms and hemorrhages can be detected quite accurately using different morphological operations applied appropriately.

Neera et al presents the method for analysis technique to the Diabetic Retinopathy diagnosis system is thus used to detect various lesions of the retina i.e. exudates, micro aneurysms and hemorrhages and there count size and location to assess the severity of the disease [14]. There are certain features present in the normal physiology of the retina which have to be differentiated from the abnormal pathology.

Goatman et al presents the method to detect the new vessels on the optic disc [15]. Detection of new vessel on the optic disc may similarly improve the detection of proliferative disease. Aim is to detect the unwanted new vessels on optic disc using the retinal photographs.

CLASSIFICATION METHOD

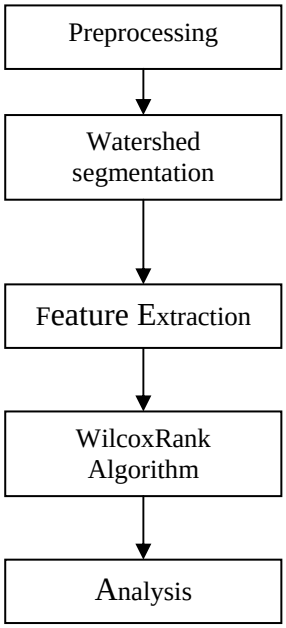


Figure 3.1 system design

*A. Preprocessing*

As shown in the figure 3.1, the bloods vessels appear in the colour retinal images are darker than the background similar to the colour of lesions like micro aneurysms and hemorrhages. The blood vessels appear most contrasted in the green channel compared to red and blue channels in RGB image. The green component was extracted from RGB component in the analysis since it shows the best contrast between the vessels and the background retina. Only the green component image is used for further processing suppressing the other two colour components.

*B. Watershed segmentation*

Watershed transform is a morphological region-based segmentation operation. Apply a morphological watershed transform which divides an image into regions based on a topographic map of the image grey level. The dividing lines between hypothetical topographical catchments areas are known as the watershed lines.

*C. Feature Extraction*

The segmented image is given as input to the feature extraction. Fifteen segment features were proposed that is GLCM feature is used to extract the feature which is based on the human observation characteristics used to recognize abnormal vessels such as their shape, position, orientation, brightness, and contrast and line density. It is a statistical method that considers the spatial relationship of pixels is the gray-level co-occurrence matrix (GLCM), also known as the gray-level spatial dependence matrix.

The Following GLCM features were extracted in our research work: Autocorrelation, Contrast, Correlation, Cluster Prominence, Cluster Shade, Dissimilarity Energy, Entropy, Homogeneity, Maximum probability , Sum of squares, Sum average, Sum variance, Sum entropy, Difference variance, Difference entropy, Information measure of correlation, information measure of correlation, Inverse difference normalized.

D. *SVM Classification*

A support vector machine was chosen as the classifier for its rapid training phase and good classification performance. The original SVM algorithm is a linear classifier which finds the best hyper plane separating two classes. However, a kernel function can be used to transform the features to a higher dimensional space. The extracted features are used to train SVM classifier. The algorithm is perfectly trained to detect the new vessels. The classifier is tested for different sets of images. The SVM estimates a probability of abnormality for each vessel segment. For the detection of abnormal images the single segment with the highest abnormality probability was selected and compared with a threshold.

## III. EXPERIMENTAL RESULTS

The group of color retinal image is taken from the STARE databases. A total of 80 images were included in the dataset: 45 conformed to new vessels and further 35 image without new vessels on the retina. These 80 images are used to train the classifier. Implementation work has been carried on MATLAB 2009. The retinal images are chosen from the directory. Fig 4.1 shows the color retinal input image.

Figure 4.1 retinal image

Fig 4.2 shows Preprocessing step, the green component was extracted from RGB component in the analysis since it shows the best contrast between the vessels and the background retina

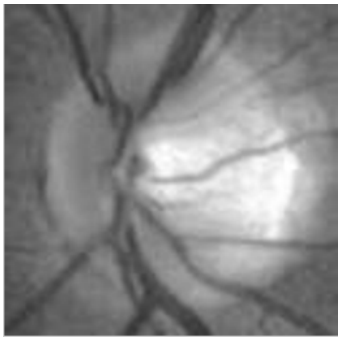

Fig 4.2 preprocessed image

Next is watershed segmentation, which is based on morphological operation. Fig 4.3 shows the segmented results.

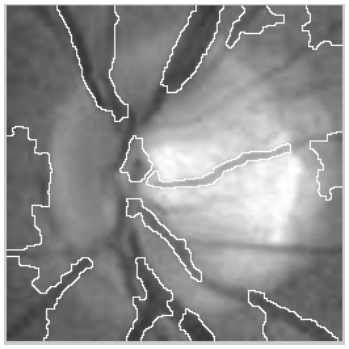

Fig 4.3 watershed segmentation

## CONCLUSION

The clinical definition of new vessels at the disc includes new vessels outside the disc but within one optic disc diameter of the disc as well as the new vessels on the disc itself. The system described here to detect the new vessels outside the disc are more similar to new vessels elsewhere on the retina than the new vessels on the disc itself, and would be detected by a different detector. There are a number of areas which merit further investigation. For example, for the new vessels on the optic disc to be detected it is necessary first to correctly locate the disc itself. The method used here is reported to detect the disc successfully. Other methods have reported similarly high detection rates. Nevertheless, it would be helpful if the detector calculated a confidence measure that allowed more doubtful disc locations to be passed to a human observer for confirmation. This suggests that improvements to the candidate selection have the potential to increase overall performance. Although the features and classifier described are fast and have good accuracy, the potential advantages of other features or classifiers could also be investigated. This paper has demonstrated an automated system which is able to distinguish normal and abnormal vasculature on the retina. It could form part of a system to reduce manual grading workload or a tool to prioritize patient grading queues.

## REFERENCES


[1] T. Walter, J. C. Klein, P. Massin, and A. Erginay, “A contribution of image processing to the diagnosis of diabetic retinopathy-detection of exudates in color fundus images of the human retina,” IEEE Trans. Med. Imag., vol. 21, no. 10, pp. 1236–1243, Oct. 2002.

[2] Michael Larsen, Jannik Godt,Nicolai Larsen, Henrik Lund-Andersen, Anne Katrin Sjølie, Elisabet Agardh,Helle Kalm, Michael Grunkin, and David R. Owens,” Automated Detection of Fundus Photographic Red Lesions in Diabetic Retinopathy”, Investigative Ophthalmology & Visual Science, Vol. 44, No. 2, February 2003.

[3] Joes Staal,Michael D. Abràmoff,Meindert Niemeijer, Max A. Viergever, and Bram van Ginneken,,”Ridge-Based Vessel Segmentation in Color Images of the Retina”, IEEE Trans. Med.Imag, vol. 23, no. 4, April 2004.

Meindert Niemeijer*, Bram van Ginneken, Joes Staal,Maria S. A. Suttorp-Schulten, and Michael

[4] D. Abràmoff,” Automatic Detection of Red Lesions in Digital Color Fundus Photographs”, IEEE Trans.Med.Imag, vol. 24, no. 5, may 2005

[5] Michal Sofka*, and Charles V. Stewart,”Retinal Vessel Centerline Extraction Using Multiscale Matched Filters, Confidence and Edge Measures”,IEEE Trans.Med. imag, vol. 25, NO. 12, Dec 2006.

[6] Harihar Narasimha-Iyer, Ali Can, Badrinath Roysam*, Charles V. Stewart, , Howard L. Tanenbaum, Anna Majerovics, and Hanumant Singh,” Robust Detection and Classification of Longitudinal Changes in Color Retinal Fundus Images for Monitoring Diabetic Retinopathy”, IEEE Transactions on biomedical engineering, vol. 53, no. 6, june 2006.

[7] Thomas Walter a,*, Pascale Massin b, Ali Erginay b, Richard Ordonez a,Clotilde Jeulin a, Jean-Claude Klein,” Automatic detection of microaneurysms in color fundus images”, Medical image analysis on science direct,vol. 11 sep 2007.

[8] Meindert Niemeijer, Bram van Ginneken, Stephen R. Russell, Maria S. A. Suttorp-Schulten, and Michael D. Abra`moff ,” Automated Detection and Differentiation of Drusen, Exudates, and Cotton-Wool Spots in Digital Color Fundus Photographs for Diabetic Retinopathy Diagnosis”, Investigative Ophthalmology & Visual Science, Vol. 48, No. 5, May 2007.

[9] Gwénolé Quellec*, Mathieu Lamard, Pierre Marie Josselin, Guy Cazuguel, Béatrice Cochener, and Christian Roux, "Optimal Wavelet Transform for the Detection of Microaneurysms in Retina Photographs", IEEE Transactions on medical imaging, vol. 27, no. 9, september 2008.

[10] Akara Sopharaka, Bunyarit Uyyanonvaraa, Sarah Barmanb,"Automatic exudate detection for diabetic retinopathy screening", ScienceAsia vol.35, 2009.

[11] Alireza Osareh, Bita Shadgar, and Richard Markham," Computational-Intelligence-Based Approach for Detection of Exudates in Diabetic Retinopathy Images", *IEEE Transactions on information technology in biomedicine, vol. 13, no. 4, july 2009.*

[12] Saiprasad Ravishankar_, Arpit Jain_, Anurag Mittal," Automated Feature Extraction for Early Detection of Diabetic Retinopathy in Fundus Images",*IEEE Transactions on medical imaging, vol.3,sep2009.*

[13] Meindert Niemeijer*, Bram van Ginneken, Michael J. Cree, Senior Atsushi Mizutani, Gwénolé Quellec, Clara I. Sánchez, Bob Zhang, Roberto Hornero, Mathieu Lamard, Chisako Muramatsu, Xiangqian Wu, Guy Cazuguel, Jane You, Agustín Mayo, Qin Li, Yuji Hatanaka, Béatrice Cochener, Christian Roux, Fakhri Karray, María García, Hiroshi Fujita, and Michael D. Abràmoff," Retinopathy Online Challenge: Automatic Detection of Microaneurysms in Digital Color Fundus Photographs", *IEEE Transactions on medical imaging, vol. 29, no. 1, january 2010.*

[14] Neera Singh, Ramesh Chandra Tripathi," Automated Early Detection of Diabetic Retinopathy Using Image Analysis Techniques", *International Journal of Computer Applications Volume 8– No.2, October 2010.*

[15] Keith A. Goatman*, Alan D. Fleming, Sam Philip, Graeme J. Williams, John A. Olson, and Peter F. Sharp," Detection of New Vessels on the Optic Disc Using Retinal Photographs", IEEE T*ransactions on medical imaging, vol. 30, no. 4, april 2011.*